



Retrospective Clinical Evaluation of Tapered Implants: 10-year Follow-up of Delayed and Immediate Placement of Maxillary Implants

Zeev Ormianer, DMD,* Dana Piek, DMD,† Shiri Livne, DMD,† David Lavi, DMD,† Gitit Zafrir, DMD,‡ Ady Palti, DMD,§ and Noga Harel, DMD†

The objective of implant therapy is to create an artificial titanium root-form shape embedded in the jawbone on which to anchor and support 1 or more replacement teeth. Brånemark introduced the 2-stage surgical protocol to achieve osseointegration in the early 1970s. This was intended to reduce bacterial infection and epithelial downgrowth and also to delay implant loading until osseointegration.¹ For the past 15 years, it has been widely accepted²⁻⁵ that immediate loading can be a safe and predictable approach in selected patients. Immediate loading is defined as the application of functional or nonfunctional load to an implant at the time of placement or within 48 hours of implant placement.⁶ This technique shortens the number of required procedures by eliminating both the submerged healing stage and implant

Objectives: To retrospectively evaluate the clinical outcome of tapered, multithreaded implants (Tapered Screw-Vent MTX; Zimmer Dental, Inc, Carlsbad, CA) with an emphasis on periimplant crestal bone status around those placed delayed and immediately in the posterior and anterior maxilla.

Methods: Chart reviews were performed on 46 patients who had been treated with 173 implants replacing one or more missing and/or unsalvageable teeth in the maxilla. Implant placement and loading was either immediate or delayed. Marginal bone changes were calculated using standardized radiographs taken at implant placement and during annual follow-up.

Results: After a mean follow-up of 119 to 121 months, implant survival rate was 99%, and implant

success rate was 97%. No discernable bone loss was evident in 85.5% of the surviving implants. Crestal bone loss was observed in 14.5% of all surviving implants: 38.5% of implants immediately loaded and 29.9% of implants with delayed loading. Twenty-one implants exhibited 1 mm of bone loss, 3 implants lost 2 mm, and 1 implant lost 3 mm. Low-density maxillary jawbone and more extensive bone remodeling required around implants immediately placed into extraction sockets were the probable causes of observed bone loss in this study.

Conclusions: Implants exhibited excellent long-term outcomes with little or no bone loss. (Implant Dent 2012;21:350-356)

Key Words: immediate placement, maxilla, implants

*Lecturer, Department of Oral Rehabilitation, The Maurice and Gabriela Goldschleger School of Dental Medicine, Tel Aviv University, Tel Aviv, Israel.

†Instructor, Department of Oral Rehabilitation, The Maurice and Gabriela Goldschleger School of Dental Medicine, Tel Aviv University, Tel Aviv, Israel.

‡Student, Department of Oral Rehabilitation, The Maurice and Gabriela Goldschleger School of Dental Medicine, Tel Aviv University, Tel Aviv, Israel.

§Clinical Professor, Department for Periodontology and Implantology, NYU Dental School, New York, NY.

Reprint requests and correspondence to: Zeev Ormianer, DMD, Department of Oral Rehabilitation, School of Dental Medicine, Tel Aviv University, Ramat Aviv, Tel Aviv 69978, Israel, Phone: +972-3-612-4224, Fax: +972-03-612-4226, E-mail: ormianer@post.tau.ac.il

exposure surgery, and thereby reduces patient discomfort. In addition, the soft tissue obtained before insertion of the final prosthesis is more mature and defined.⁷ Another advantage of immediate loading is the rapid delivery of both interim and final prostheses. Immediate loading is also fraught with risk, which includes higher chances of failure due to micromovements of the implant, and an inability to predict

the esthetic outcomes of the final restoration.⁸ These failures are mainly attributed to mistreating of the bone-implant interphase; inappropriate occlusal scheme, inadequate implant design and manufacturing, and faulty rehabilitation.⁹⁻¹¹

Immediate implantation is the placement of implants into fresh extraction sockets. This is an approach that has been reviewed extensively.^{2-5,12-15}

Success with the procedure requires apically or laterally anchoring the implant to the surrounding socket walls for primary stability. Rather than using the socket as a guide for implant positioning, an osteotomy is prepared inside the socket to gain a more favorable prosthetic location and to provide a freshly bleeding bony interface with the implant surface. It was previously thought that immediate implantation could minimize bone alterations after tooth extraction, but research¹⁶ has shown that dimensional ridge resorption can still occur. Nonetheless, the dental literature¹⁷⁻¹⁹ also shows similar survival implant rates regardless of placement time, but other aspects such as implant success and esthetic outcomes are still being debated.²⁰

An atraumatic surgical technique and initial implant stability are important for avoiding implant micromovements that can cause crestal bone loss and failure of osseointegration.^{21,22} Studies^{10,11} have shown that achieving functional bone-to-implant contact without imposition of a fibrous tissue barrier is dependent on implant micromovements not exceeding 100 to 150 μm. Implant stability can reportedly be improved by connecting implants by a bar or framework, reinforcing provisional restorations with metal, placing implants a minimum of 10 mm in length, and choosing screw-design implants rather than cylindrical implants.²⁻⁵ Implant design has also been reported to contribute to the success rate of immediately loaded implants, with roughened surfaces achieving better survival rates than machined surfaces.¹²⁻¹⁴ Avila et al⁸ reported that immediately loaded implants with roughened and machined surfaces achieved 94.1% and 88.8% success, respectively.

It should be noted that a well-designed final restoration will determine the long-term treatment outcome. The location of the implants, parallel arrangement, and stabilization may reduce the risk of overload, given the superior load distribution of a larger bone-to-implant surface.¹⁵ Success rates for splinted implant restorations have been reported to be higher (94.7%) than separate, freestanding

restorations (88.8%).^{23,24} Occlusal scheme is one of the crucial aspects of preventing implant overload; although fabricating the restoration, occlusal forces should be paralleled to the long axis of implants. It can be achieved by avoiding excursion movements especially during immediate loading procedure. Patients with parafunctional habits (eg, bruxing, clenching) are not good candidates for this procedure, and they should be informed of the potential risks and reduced success rates due to excessive forces on implants.^{25,26}

Immediate loading in the mandibular symphysis may be most predictable because of the presence of usually dense, compact bone that provides the best conditions for this application. An implant placed in compact bone with no bony defects has a higher probability of achieving initial stability and is better capable of absorbing occlusal load than in other jaw locations.^{11,27,28} There is much less information about immediate loading and immediate implantation in the upper jaw. The maxilla is more challenging for implant placement due to anatomical characteristics that are not present in edentulous mandibles: the nasal cavities and maxillary sinuses, in combination with the soft trabecular bone. For these reasons, maxillary implants have exhibited a slightly higher failure rate than mandibular implants, especially when immediately loaded.²⁹⁻³¹

This article reports on a retrospective comparison of implants that were placed in the maxilla using immediate and traditional delayed techniques.

MATERIALS AND METHODS

The clinical outcome of tapered, multithreaded implants with microtextured surfaces (Tapered Screw-Vent MTX; Zimmer Dental, Inc, Carlsbad, CA) was retrospectively examined. All implants were placed and restored by one author (A.P.) in a private dental practice. Patients were treated for one or more missing and/or unsalvageable teeth in the upper jaw, and they met general inclusion criteria for dental implant treatment (Table 1). Patient charts were reviewed, and data were retrospectively entered into spreadsheets on a personal computer.

After careful review of their medical and dental histories, subjects were subjected to detailed clinical and radiographic examinations, evaluated for oral hygiene, and assessed for their ability to commit to long-term follow-up. For each patient, the volume and location of available bone and esthetic and functional needs were evaluated through diagnostic workup. A prosthetic wax-up and surgical template were fabricated to allow guided placement of the implants relative to the planned prosthesis. The treatment plan and alternative options were discussed, and signed informed consent was obtained from each patient before treatment.

When extractions were carried out, an atraumatic technique was used to minimally impinge on the surrounding tissues, and the sockets were thoroughly debrided. A surgical template was used for osteotomies, and implants were placed in accordance with the product's instructions for use. Criteria for immediate placement of implants were initial implant stability, 4-walled postextraction sites, and implant-alveolar bone gap of no more than 2 mm. When implants were placed into fresh extraction sites, coronal gaps greater than 1 mm were grafted with

Table 1. Criteria for Implant Treatment

Inclusion	At least 18 years of age Adequate available bone to accommodate an implant Systemically and dentally healthy Demonstrated ability to maintain oral hygiene Willingness and ability to commit to follow-up Provide signed informed consent
Exclusion	Lack of skeletal maturity Ridges that required significant augmentation for implant site development Uncontrolled diseases or conditions that could impede bone healing or soft tissue health Mental, emotional, or lifestyle factors that could adversely impact treatment and follow-up

Table 2. Criteria for Implant Evaluations

Clinical survival	Implant is immobile with manually tested
	No periimplant radiolucency
	No irresolvable clinical symptoms, such as pain, discomfort, numbness, infection
	No irresolvable mechanical problems
	No fractured components
	Implant is fully functioning according to its intended prosthodontic purpose
Clinical success	Meets implant survival criteria
	Absence of fractured components
	Absence of nonfailure-related adverse events
	Periimplant bone loss does not exceed 1.5 mm
	Meets the patient's clinical and esthetic needs
	Meets the patient's expectations
	Cumulative implant survival is at least 90% after 5 years
Cumulative implant success is at least 90% after 5 years	

autogenous bone or β -tricalcium phosphate mixed with blood and covered with a resorbable barrier membrane (BioMend; Zimmer Dental, Inc). Some implants were subjected to delayed loading after a conventional submerged healing period, whereas other implants were immediately loaded with provisional restorations. The decision to perform immediate loading of implants was made to avoid removable provisional restorations in patients who were reluctant with such a provisional. The implants immediately loaded were tested for reverse torque with a threshold value was 20 N.cm.

Marginal bone changes were calculated from implant neck to the crestal bone level using standardized radiographs taken at implant placement (baseline) and during annual follow-up.

A transparent implant template with a 1.0-mm grid enlarged 25% to help compensate for radiologic distortion was placed over each radiograph to calculate marginal bone changes relative to the top of the implant. Bone loss was recorded in incremental ranges of 0 to 1 mm, 1 to 1.5 mm, 1.5 to 2 mm, and greater than 2 mm.

Survival and Success Criteria

Table 2 summarizes the criteria for evaluating implant clinical survival and clinical success. Survival meant that an implant was immobile when manually tested, did not exhibit periimplant radiolucency, had no irresolvable clinical symptoms or mechanical problems, was clinically intact, and fully met its prosthodontic purpose. All clinically

failed implants were removed from the patients and recorded as failures. Implants were considered successful if they met the implant survival criteria, had no nonfailure-related adverse events, did not have periimplant bone loss that exceeded 1.5 mm, after 10 years of follow-up, and met the patient's clinical and esthetic needs and expectations.

Statistical Methods

Study variables were summarized by the time of placement of the dental implant: immediate or delayed. For each analysis group, categorical study end points were summarized as frequencies and percentages at each level of the variable, and continuous variables were summarized using descriptive statistics (N, mean, median, standard deviation, minimum, and maximum). Between-group comparisons of categorical end points were made using either Fisher exact test (dichotomous end points) or the χ^2 test (polychotomous end points). Between-group comparisons of continuous variables were made using the Student *t* test with sample variances pooled. An (folded) *F* test was used to assess the equality of sample variances between the 2 groups, and the Satterthwaite *t* test and Wilcoxon nonparametric rank-sum test were also performed to accommodate instances when the assumption of equal sample variances in the pooled *t* test was unmet. Statistical significance was inferred at the nominal level of type I (α)

Table 3. Distribution of Patients and Implants

Patients	Sex (No. of Patients)		Health Risks (No. of Patients)		Age, Mean (Range) (Y)
	Males	Females	Periodontitis	Smokers	
	19	27	29	1	50.54 (18–75)
Implants	Time of Implant Placement*		Implant Lengths (No. Placed)		
		Implant Diameter (mm)	10 mm	13 mm	16 mm
	Delayed	3.7	13*	64	3
		4.7	6	18	4
Immediate	3.7	0	34	15	
	4.7	5	9	2	
Restorations	Time of Implant Loading (No. of Implants)†		Types of Restorations (No. of Implants)		
	Delayed	Immediate	Time of Implant Placement‡	Fixed Partial Denture Multiple Unit	Single Unit
	32	42	Delayed	98	9
	75	23	Immediate	58	7

*One (1) implant failed in this group

†Delayed = Loaded after osseointegration; Immediate = Loaded at time of implant placement.

‡Delayed = Healed extraction site or existing edentulous site; Immediate = Fresh extraction site.

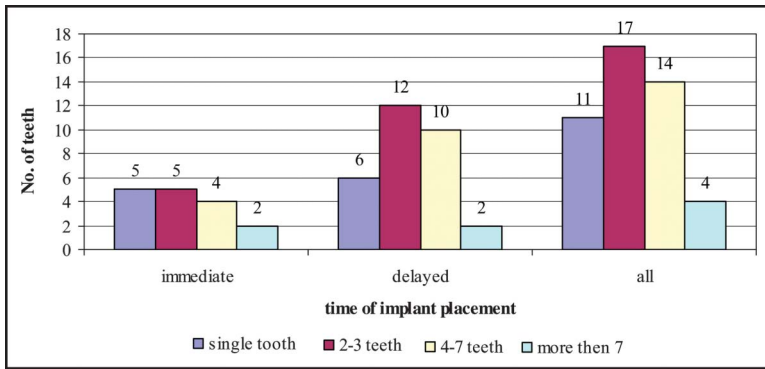


Fig. 1. Number of teeth replaced per patient.

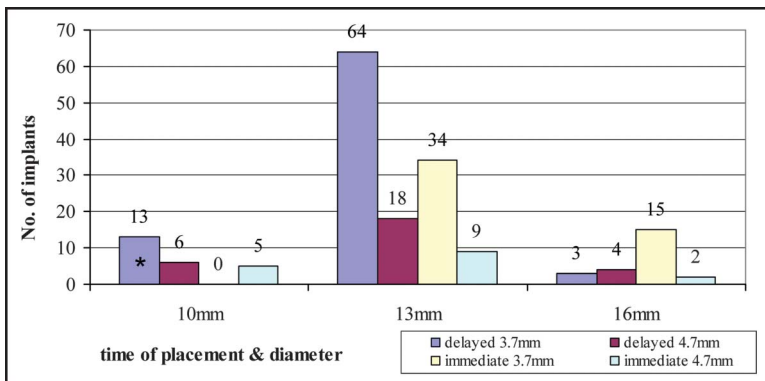


Fig. 2. Implants length (by diameter and time of placement).

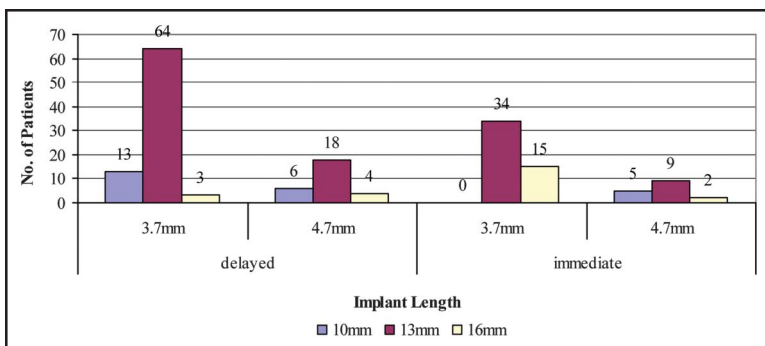


Fig. 3. Implant distribution (time of implant placement).

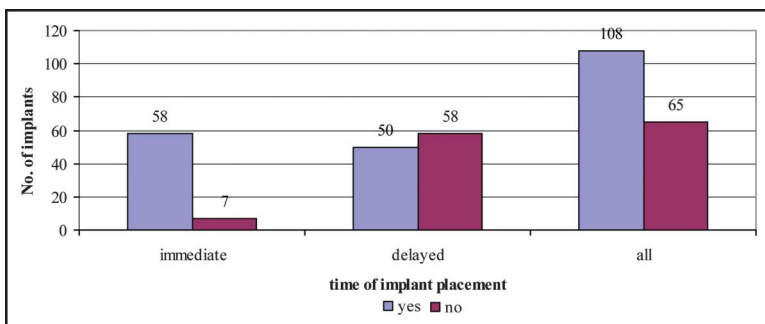


Fig. 4. Bone graft use.

error, and significance levels were not adjusted for multiplicity. All analyses were performed using SAS (SAS, Inc, Cary, NC) for the personal computer on the Windows XP operating system.

RESULTS

Table 3 presents the distribution of patients and implants. In the study population of 46 subjects, 16 (35%) had immediate and 30 (65%) had delayed placement of dental implants. Between the 2 placement groups, average age at surgery ($P = 0.99$, 50.6 years immediate and 50.5 years delayed placement) and sex ($P = 0.53$, 50% [8 of 16] males with immediate and 36.7% [11 of 30] males with delayed placement) did not statistically differ. Health risks did not significantly differ ($P > 0.99$) between immediate (62.5%, 10/16) and delayed (66.7%, 20/30) placement groups. However, length of follow-up was statistically significant at the nominal level (Satterthwaite t test, $P = 0.03$), and it averaged 121.1 months (range, 104–127 months) in immediate and 119.4 months (range, 102–126 months) in delayed placement groups.

There were a total of 173 implants placed in the 46 study subjects; of these, 65 implants (38%) were placed immediately into fresh extraction sockets and 108 implants (62%) (delayed placement group) were placed in healed extraction sites. Implants were placed in the left quadrant 55% (36 of 65) of the time in the immediate placement and 52% (56 of 108) of the time in the delayed placement group. Placement, by quadrant, did not significantly differ between the groups at the implant level ($P = 0.75$). The type of implant also did not significantly differ between immediate and delayed placement groups ($P = 0.60$). The number of implants placed did not significantly differ between the placement groups ($P = 0.14$) (Fig. 1). Length of implants (Fig. 2) significantly differed ($P = 0.001$) between immediate and delayed placement groups, whereas implant diameters (Fig. 3) did not significantly differ ($P > 0.99$).

The use of bone graft (Fig. 4) at the time of implant placement significantly differed between the 2 study groups ($P < 0.0001$). The study groups significantly differed with respect to loading of

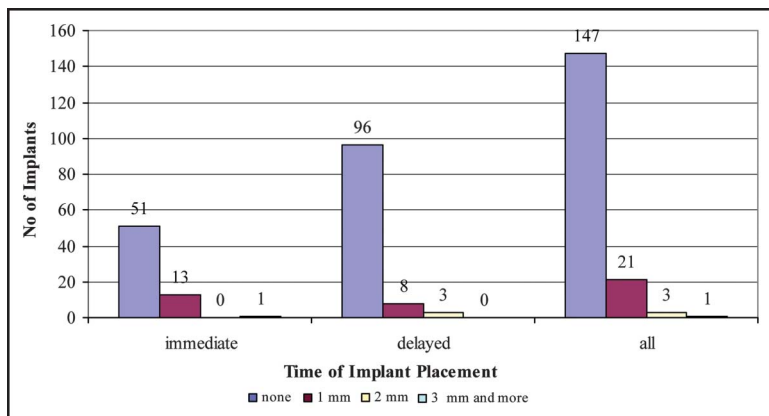


Fig. 5. Bone loss amount.

the prosthesis ($P < 0.0001$). Immediate loading was more prevalent (65%) in the immediate placement group than in the delayed placement group (30%). The distribution of specific teeth replaced significantly differed between the study groups ($P = 0.008$). Premolars (first and/or second) were replaced in 34% (22 of 65) with immediate and in 46% (50 of 108) with delayed placement. Molars (first and/or second) were replaced in 12% (8 of 65) with immediate and 28% (30 of 108) with delayed placement. Incisors (lateral and/or central) were replaced in 39% (25 of 65) with immediate and 15% (16 of 108) with delayed placement. Cuspids were replaced in 15% (10 of 65) with

immediate and 11% (12 of 108) with delayed placement.

Adverse events are presented in Table 4. The study groups did not significantly differ ($P = 0.31$) in the frequencies of prosthesis-related adverse events because most teeth were event free (94% [61 of 65] immediate and 89% [95 of 107] delayed placement). Porcelain fracture was the most prevalent prosthesis-related adverse event ($n = 2$ immediate and $n = 10$ delayed placement), whereas infrequent reports of cement failure ($n = 0$ immediate and $n = 1$ delayed placement), debonding ($n = 1$ immediate and $n = 0$ delayed placement), and framework fracture ($n = 1$

immediate and $n = 1$ delayed placement) were also noted. Bone loss (Fig. 5) (any/none) did not significantly differ between the 2 study groups ($P = 0.02$). The majority of implants had no bone loss. The 3 bone losses of >2 mm observed in the delayed placement group were all 3 mm, and all patients had periodontitis as a comorbidity. The first case, observed at 116 months, was a 35-year-old woman (patient 24) who underwent maxillary right second molar replacement with a 13 mm (length) by 3.7 mm (diameter) implant. A total of 3 implants were placed and immediately loaded. The second case, observed at 120 months, occurred in a 70-year-old man (patient 23) who underwent maxillary left first premolar replacement with a 16 mm (length) by 4.7 mm (diameter) implant. A total of 3 teeth were replaced, and immediate loading occurred. The third case, observed at 121 months, was a 55-year-old woman (patient 36) who underwent maxillary left first molar replacement with a 13 mm (length) by 3.7 mm (diameter) implant. A total of 6 teeth were replaced, and immediate loading did not occur.

There was a single implant failure. An infection in a 60-year-old man with periodontitis as a comorbidity occurred in the first left maxillary premolar. The infection was localized, and the other 7

Table 4. Adverse Events

Patient Number	Location		Implant (mm)		Problem Area		Type	Resolution	Implant Status
	Side	Tooth	Diameter	Length	Implant	Prosthesis			
2	L	2Bi	4.7	13	No	Yes	Cem	RC	Successful
8	R	2Bi	3.7	13	No	Yes	PF	NC	Successful
11	R	2Bi	3.7	13	No	Yes	PF	NC	Successful
21	L	Cus	3.7	13	No	Yes	PF	NC	Successful
	R	Lat	3.7	13	No	Yes	PF	NC	Successful
	R	1Mo	3.7	13	No	Yes	PF	NC	Successful
25	R	Lat	3.7	13	No	Yes	PF	NC	Successful
30	L	2Bi	4.7	13	No	Yes	PF	NC	Successful
31	R	2Mo	4.7	10	No	Yes	PF	NC	Successful
36	R	Cus	3.7	13	No	Yes	PF	NC	Successful
	L	Cus	3.7	13	No	Yes	PF	NC	Successful
38	R	Lat	3.7	13	No	Yes	FF	NR	Successful
55	R	1Bi	3.7	13	No	Yes	PF	NC	Successful
56	R	2Bi	3.7	13	No	Yes	FF	NR	Successful
58	R	Cus	3.7	10	No	Yes	CF	WFS	Successful
	R	1Bi	3.7	10	Yes	No	FTI2	WFS	Unsuccessful
	L	1Bi	3.7	10	No	Yes	PF	WFS	Successful

L, left; R, right; 2Bi, second premolar; Cus, cuspid; Lat, lateral incisor; 1Mo, first molar; 2Mo, second molar; 1Bi, first premolar; Cem, cement failure; PF, porcelain fracture; FF, framework fracture; CF, crown fracture; FTI2, failed to integrate infection; RC, re-cemented crown; NC, placed new crown; NR, placed new restoration; WFS, withdrawn from study.

implants did not experience infection. Of the 8 maxillary dental implants (4 right and 4 left), all were 10 mm in length and were 3.7 mm in width. Of these 8 implants, 2 experienced prosthesis-related adverse events: 1 porcelain fracture (first premolar [left]); and 1 cement failure (cuspid [right]). Follow-up for the 7 prostheses, which did not experience failure, was 121 months. Cumulative survival rates were 99.4% (n = 172/173) for all implants placed; 99.1% (107/108) for all implants placed into healed edentulous sites; and 100% (65/65) for all implants immediately placed into fresh extraction sites.

DISCUSSION

The placement of implants into fresh extraction sockets was first reported in the late 1970s.³² This treatment option has been widely reviewed during the past decade^{17-19,33}, and it shows favorable results. Some recent studies present patient selection guidelines for achieving good outcomes.^{17,34-38} Under a controlled procedure, immediate implants may be successfully placed into debrided infected alveolar sockets.³⁹ In the anterior maxilla, there are several advantages for the immediate placement of an implant after tooth extraction. Unfavorable ridge width usually develops and may create palatolabial discrepancy between the implant and the restoration. Thus, placing an implant immediately after tooth extraction can enable implant positioning in a close to ideal location.⁴⁰⁻⁴³

The finding in the present study that 85.5% of the surviving implants exhibited no discernable periimplant bone loss raised the question as to why the remaining 12.2% of the implants exhibited any bone loss at all. Within the bone loss group, implants placed into immediate extraction sockets exhibited a 21.5% (14 of 65) higher bone loss rate than implants placed into existing healed edentulous sites (11 of 107). The presence of circumferential gaps around implants' body at the time of placement into extraction sockets may account for the majority of implants (21 of 172) that exhibited the traditional 1 mm saucerization. However, 3 implants (3 of 172,

all 3 implants were placed into existing healed edentulous sites) lost 2 mm of bone radiographically.

The implants used in this study featured a 1-mm turned (machined) cervical collar above their microtextured surfaces. Although short-term clinical studies have demonstrated increased bone attachment to roughened surfaces as compared with machined surfaces,^{44,45} no studies were identified that clinically demonstrated the ability of roughened surfaces to prevent crestal bone resorption. Conversely, implants with fully roughened cervical collars⁴⁶ have demonstrated short-term and long-term periimplant bone loss rates comparable to conventional machined titanium implants: approximately 1.2 mm from placement to the first year of clinical loading followed by approximately 0.2 mm of bone loss thereafter until a steady state was achieved.⁴⁷ Based on these findings, it is doubtful that the 1-mm machined cervical collar contributed to the observed crestal bone loss in the present study.

To assess the complex host of variables that affected the long-term outcome of implants in this study, data were analyzed on both a per-implant and per-patient basis. The selected statistical analyses were designed to investigate the relationships between the variables and to determine whether the observed differences were statistically significant, although implant survival and implant success rates often tend to slowly decline after 5 years in function.

CONCLUSION

The findings of the present study suggest that the rehabilitation of 1 or more missing and/or unsalvageable teeth in the upper jaw by immediately placed implants is a predictable treatment option. After a long-term follow-up, the success rate was in accordance with the reports of other studies (92.5%–100%).⁴⁸⁻⁵²

DISCLOSURE

The authors claim to have no financial interest, either directly or indirectly, in the products or information mentioned in this article.

REFERENCES

1. Brånemark PI, Hansson BO, Adell R, et al. Osseointegrated implants in the treatment of the edentulous jaw. Experience from a 10-year period. *Scand J Plast Reconstr Surg Suppl.* 1977;16:1-132.
2. Chiapasco M, Gatti C, Rossi E, et al. Implant-retained mandibular overdentures with immediate loading. A retrospective multicenter study on 226 consecutive cases. *Clin Oral Implants Res.* 1997;8:48-57.
3. Tarnow DP, Emtiaz S, Classi A. Immediate loading of threaded implants at stage 1 surgery in edentulous arches: ten consecutive case reports with 1- to 5-year data. *Int J Oral Maxillofac Implants.* 1997;12:319-324.
4. Lefkove MD, Beals RP. Immediate loading of cylinder implants with overdentures in the mandibular symphysis: the titanium plasma-sprayed screw technique. *J Oral Implantol.* 1990;16:265-271.
5. Randow K, Ericsson I, Nilner K, et al. Immediate functional loading of Brånemark dental implants. An 18-month clinical follow-up study. *Clin Oral Implants Res.* 1999;10:8-15.
6. Laney WR. *Glossary of Oral and Maxillofacial Implants.* Chicago, IL: Quintessence; 2007:73.
7. Misch CE, Hahn J, Judy KW, et al. Workshop guidelines on immediate loading in implant dentistry. *J Oral Implantol.* 2004;30:283-288.
8. Avila G, Galindo P, Rios H, et al. Immediate implant loading: current status from available literature. *Implant Dent.* 2007;16:235-245.
9. Linkow LI. Endosseous blade-vent implants: a two-year report. *J Prosthet Dent.* 1970;23:441-448.
10. Linkow LI, Glassman PE, Asnis ST. Macroscopic and microscopic studies of endosteal bladevent implants (six month dog study). *Oral Implantol.* 1973;3:281-309.
11. Cochran DL, Morton D, Weber HP. Consensus statements and recommended clinical procedures regarding loading protocols for endosseous dental implants. *Int J Oral Maxillofac Implants.* 2004;19 (suppl):109-113.
12. Piattelli A, Paolantonio M, Corigliano M, et al. Immediate loading of titanium plasma-sprayed screw-shaped implants in man: a clinical and histological report of two cases. *J Periodontol.* 1997;68:591-597.
13. Corso M, Sirota C, Fiorellini J, et al. Clinical and radiographic evaluation of early loaded free-standing dental implants with various coatings in beagle dogs. *J Prosthet Dent.* 1999;82:428-435.

14. Degidi M, Petrone G, Iezzi G, et al. Histologic evaluation of a human immediately loaded titanium implant with a porous anodized surface. *Clin Implant Dent Relat Res.* 2002;4:110–114.
15. Misch CE, Scortecchi GM. Immediate load applications in implant dentistry. In: Misch C. *Dental Implant Prosthetics*. St Louis, MO: Elsevier Mosby; 2005: 531–567.
16. Botticelli D, Berglundh T, Lindhe J. Hard-tissue alterations following immediate implant placement in extraction sites. *J Clin Periodontol.* 2004;31:820–828.
17. Schwartz-Arad D, Chaushu G. Placement of implants into fresh extraction sites: 4 to 7 years retrospective evaluation of 95 immediate implants. *J Periodontol.* 1997;68:1110–1116.
18. Mayfield LJA. *Immediate, Delayed and Late Submerged and Transmucosal Implants. Proceeding of the 3rd European Workshop on Periodontology, Ittingen, Switzerland.* Berlin, Germany: Quintessence; 1999:520–534.
19. Chen ST, Wilson TG Jr, Hammerle CH. Immediate or early placement of implants following tooth extraction: review of biologic basis, clinical procedures, and outcomes. *Int J Oral Maxillofac Implants.* 2004;19(suppl):12–25.
20. Quirynen M, Van Assche N, Botticelli D, et al. How does the timing of implant placement to extraction affect outcome? *Int J Oral Maxillofac Implants.* 2007;22(suppl):203–223.
21. Gapski R, Wang HL, Mascarenhas P, et al. Critical review of immediate implant loading. *Clin Oral Implants Res.* 2003;14:515–527.
22. Roberts WE, Smith RK, Zilberman Y, et al. Osseous adaptation to continuous loading of rigid endosseous implants. *Am J Orthod.* 1984;86:95–111.
23. Kim Y, Oh TJ, Misch CE, et al. Occlusal considerations in implant therapy: clinical guidelines with biomechanical rationale. *Clin Oral Implants Res.* 2005;16:26–35.
24. Misch CE, Wang HL, Misch CM, et al. Rationale for the application of immediate load in implant dentistry: part II. *Implant Dent.* 2004;13:310–321.
25. Jaffin RA, Kumar A, Berman CL. Immediate loading of dental implants in the completely edentulous maxilla: a clinical report. *Int J Oral Maxillofac Implants.* 2004;19:721–730.
26. Colomina LE. Immediate loading of implant-fixed mandibular prostheses: a prospective 18-month follow-up clinical study—preliminary report. *Implant Dent.* 2001;10:23–29.
27. Misch CE, Wang HL, Misch CM, et al. Rationale for the application of immediate load in implant dentistry: part I. *Implant Dent.* 2004;13:207–217.
28. Aparicio C, Rangert B, Sennerby L. Immediate/early loading of dental implants: a report from the Sociedad Espanola de Implantes World Congress consensus meeting in Barcelona, Spain, 2002. *Clin Implant Dent Relat Res.* 2003;5:57–60.
29. Friberg B, Nilson H, Olsson M, et al. Mk: the self-tapping Brånemark implant: 5-year results of a prospective 3-center study. *Clin Oral Implants Res.* 1997;8:279–285.
30. Ormianer Z, Palti A. The use of tapered implants in the maxillae of periodontally susceptible patients: 10-year outcomes. *Int J Oral Maxillofac Implants.* 2012;27:442–448.
31. Penarrocha-Diago M, Demarchi CL, Maestre-Ferrin L, et al. A retrospective comparison of 1,022 implants: immediate versus nonimmediate. *Int J Oral Maxillofac Implants.* 2012;27:421–427.
32. Schulte W, Kleineikenscheidt H, Lindner K, et al. [The Tubingen immediate implant in clinical studies]. *Dtsch Zahnarztl Z* 1978;33:348–359.
33. Berglundh T, Persson L, Klinge B. A systematic review of the incidence of biological and technical complications in implant dentistry reported in prospective longitudinal studies of at least 5 years. *J Clin Periodontol.* 2002;29(suppl 3): 197–212; discussion 32–33.
34. Rosenquist B. A comparison of various methods of soft tissue management following the immediate placement of implants into extraction sockets. *Int J Oral Maxillofac Implants.* 1997;12:43–51.
35. Douglass GL, Merin RL. The immediate dental implant. *J Calif Dent Assoc.* 2002;30:362–365, 68–74.
36. Sclar AG. Strategies for management of single-tooth extraction sites in aesthetic implant therapy. *J Oral Maxillofac Surg.* 2004;62(9 suppl 2):90–105.
37. Palti A. Immediate placement and loading of implants in extraction sites: procedures in the aesthetic zone. *Dent Implantol Update.* 2004;15:41–47.
38. Becker W. Immediate implant placement: diagnosis, treatment planning and treatment steps/or successful outcomes. *J Calif Dent Assoc.* 2005;33: 303–310.
39. Casap N, Zeltser C, Wexler A, et al. Immediate placement of dental implants into debrided infected dentoalveolar sockets. *J Oral Maxillofac Surg.* 2007;65:384–392.
40. Lazzara RJ. Immediate implant placement into extraction sites: surgical and restorative advantages. *Int J Periodont Restor Dent.* 1989;9:332–343.
41. Gelb DA. Immediate implant surgery: three-year retrospective evaluation of 50 consecutive cases. *Int J Oral Maxillofac Implants.* 1993;8:388–399.
42. Hui E, Chow J, Li D, et al. Immediate provisional for single-tooth implant replacement with Brånemark system: preliminary report. *Clin Implant Dent Relat Res.* 2001;3:79–86.
43. Kan JY, Rungcharassaeng K, Lozada J. Immediate placement and provisionalization of maxillary anterior single implants: 1-year prospective study. *Int J Oral Maxillofac Implants.* 2003;18: 31–39.
44. Trisi P, Lazzara R, Rao W, et al. Bone-implant contact and bone quality: evaluation of expected and actual bone contact on machined and osseointegrated implant surfaces. *Int J Periodont Restor Dent.* 2002;22:535–545.
45. Trisi P, Marcato C, Todisco M. Bone-to-implant apposition with machined and MTX microtextured implant surfaces in human sinus grafts. *Int J Periodont Restor Dent.* 2003;23:427–437.
46. Chou CT, Morris HF, Ochi S, et al. Part II: crestal bone loss associated with the Ankylos implant: loading to 36 months. *J Oral Implantol.* 2004;30:134–143.
47. Astrand P, Engquist B, Dahlgren S, et al. Astra Tech and Brånemark system implants: a 5-year prospective study of marginal bone reactions. *Clin Oral Implants Res.* 2004;15:413–420.
48. Degidi M, Piattelli A, Gehrke P, et al. Five-year outcome of 111 immediate nonfunctional single restorations. *J Oral Implantol.* 2006;32:277–285.
49. Degidi M, Piattelli A, Carinci F. Immediate loaded dental implants: comparison between fixtures inserted in post-extractive and healed bone sites. *J Craniofac Surg.* 2007;18:965–971.
50. Ferrara A, Galli C, Mauro G, et al. Immediate provisional restoration of post-extraction implants for maxillary single-tooth replacement. *Int J Periodont Restor Dent.* 2006;26:371–377.
51. Petrunaro PS. An update on implant placement and provisionalization in extraction, edentulous, and sinus-grafted sites. A clinical report on 3200 sites over 8 years. *Compend Contin Educ Dent.* 2008;29:288–294, 296, 298–300.
52. Villa R, Rangert B. Early loading of interforaminal implants immediately installed after extraction of teeth presenting endodontic and periodontal lesions. *Clin Implant Dent Relat Res.* 2005;7(suppl 1): S28–S35.