

MAXILLARY SINGLE-TOOTH REPLACEMENT UTILIZING A NOVEL CERAMIC RESTORATIVE SYSTEM: RESULTS TO 30 MONTHS

Zeev Ormianer, DMD
Guido Schirotli, MD, DDS

KEY WORDS

Tapered screw implants
Ceramic restorations
Single-tooth replacement

This study reports on the first longitudinal results of an alumina (70%)-zirconia (30%) ceramic restorative system for implant-supported, single-tooth replacement in the anterior maxillary jaw. Eighteen patients (9 men, 9 women, mean age = 42.4 years) were treated with 22 implants placed into 19 extraction sockets and 3 residual ridges. Eight implants were immediately loaded with nonoccluding provisional prostheses. All implants were definitively loaded with fully occluding ceramic restorations after osseointegration and soft tissue maturation. Patients were monitored from 7 to 30 months (mean = 18.1 months) after loading. All implants osseointegrated and were successfully restored. One case of abutment screw loosening occurred because of patient parafunction (bruxing), and another patient reported chewing pain attributed to malocclusion. Both problems were successfully resolved without further incidence. Within the context of this study, single-tooth replacement in the anterior maxillary jaw was successfully achieved with alumina-zirconia ceramic single-tooth restorations with up to 30 months of clinical function.

INTRODUCTION

Implant-supported, single-tooth restorations in the anterior maxillary jaw have traditionally posed a number of clinical and esthetic challenges. Ridge resorption patterns may necessitate placement of implants with a labial inclination and complicate the ability to achieve an abutment emergence profile that is parallel with adjacent dentition.¹ Lower-density maxillary bone traditionally results in approximately a 10% higher implant

failure rate compared with the mandible.¹ In partially edentulous cases, ceramometal restorations can sometimes appear darker than the adjacent natural dentition.²

Clinical demands for improved esthetics have led to the development of all-ceramic restorative systems as esthetic alternatives to ceramometal restorations.³⁻⁵ Their excellent restorative properties include low thermal conductivity and diffusivity, low electrical conductivity,⁶ and a translucency that minimizes

Zeev Ormianer, DMD, is in private practice in prosthodontics, Ramat Gan, Israel. Address correspondence to Dr Ormianer at 143 Bialik Street, Ramat-Gan 52523, Israel (e-mail: drzeev@ormianer.com).

Guido Schirotli, MD, DDS, is in private practice in implants and general dentistry, Genova, Italy.

TABLE 1
Patient-selection criteria

Inclusion	Exclusion
One or more missing/hopeless teeth in the maxillary jaw	Failure to meet the inclusion criteria, including the following acute or uncontrolled health risk factors: cardiac infarction within the past 12 mo, stroke, bleeding disorders, uncontrolled diabetes, osteoporosis, metabolic diseases, severe autoimmune deficiencies, cancer, destructive parafunctional habits
Adequate bone volume for implant placement	
No contraindicating health risk factors*	
Commitment to hygiene	
Willingness to meet follow-up requirements	

*Smokers were not excluded from this study.

gingival shadowing and creates an appearance of tooth vitality.^{5,7} When used on dental implants, however, titanium abutments can block the transmission of light through all-ceramic crowns and make restorations appear duller than the adjacent dentition.² Over time, porcelain degradation from toothbrushing may increase this visual disparity.^{2,8} Implant abutments may also produce an unsightly metallic smile line that can become more pronounced with gingival recession and oxidation.^{2,9,10}

New porcelain veneering techniques can be implemented to help increase the appearance of translucency in restorations with underlying metal, and improved labial margin designs can help mitigate the problem of metallic smile lines.^{2,9,11} For example, the application of porcelain to the collar region of gold abutments may help preserve esthetics in the event of future gingival recession,^{1,12} but these restorative techniques require greater time and technical expertise, which can add additional laboratory cost.²

Several manufacturers have introduced ceramic restorative systems for implants, but preparation time and less-than-optimal restorative materials have resulted in slow market growth.¹³ A new ceramic restorative system (PureForm, Zimmer Dental Inc,

Carlsbad, Calif) that enables porcelain to be applied directly to an opaque ceramic base instead of a metal framework has been evaluated for strength and esthetic results, but no longitudinal follow-up data have been reported.¹³ This prospective study evaluated the clinical performance of the system on tapered screw dental implants placed in the maxillae of humans.

MATERIALS AND METHODS

Patient selection and evaluation

Study candidates presented with 1 or more missing or hopeless maxillary teeth in the authors' private dental practices located in Israel (Z.O.) and Italy (G.S.). All patients were subjected to a preliminary evaluation that included careful review of their medical and dental histories, detailed clinical and radiographic examinations, oral hygiene status, and ability to commit to a long-term treatment plan. Those patients who met strict inclusion criteria (Table 1)¹⁴⁻¹⁶ were admitted into the study after treatment alternatives were explained and signed informed consent was obtained.

Diagnostic evaluations were performed to assess the volume and location of available bone and the esthetic and functional

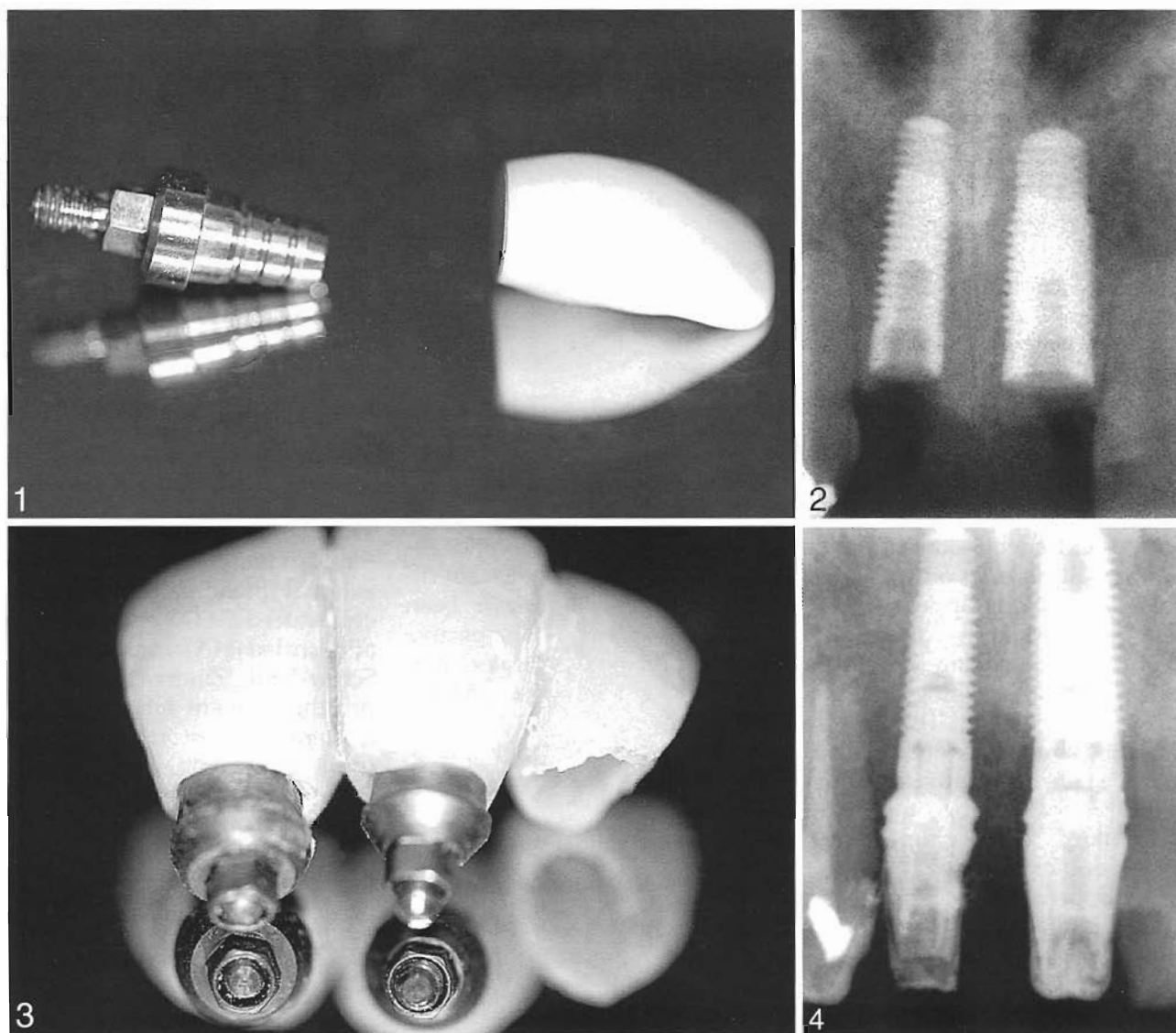
needs of the case relative to the desires of the patient. A study cast was fabricated and mounted on a semiadjustable articulator utilizing a face bow transfer and vertical registration to determine the jaw relationships, available occlusal dimension, proposed implant position, crown-root ratio, and potential complications. This enabled fabrication of a prosthetic wax-up and a surgical template to guide implant placement relative to the planned restoration.

Implant and restorative components

This study utilized a tapered screw implant design with a triple external thread pattern and a microtextured (MTX) or hydroxyapatite-coated (HA) surface (Tapered Screw-Vent, Zimmer). Definitive prostheses were fabricated with a ceramic restorative system (PureForm) containing 6 alumina (70%)-zirconia (30%) copings shaped like prepared natural teeth and titanium core abutments that provided a machined interface between the prostheses and implants (Figure 1).

Surgical procedures

The patient was prepared for surgery. Anesthesia was accomplished via local infiltration with or without nitrous oxide sedation, depending on the needs of the patient and the preference of the clinician. In cases with hopeless dentition, the periodontal ligament was severed and the tooth was atraumatically avulsed to preserve the surrounding bony architecture for the immediate placement and stabilization of an implant. In some cases, the tooth was sectioned or filed interproximally to facilitate its dislocation and removal. Soft tissue remnants were carefully debrided from the extraction socket with curettes



FIGURES 1–4. FIGURE 1. The restorative system consists of a tooth-shaped ceramic coping and a titanium core abutment that forms a machined interface with the implant. FIGURE 2. Two implants (Tapered Screw-Vent, Zimmer Dental Inc) are placed in the location of the maxillary central incisors. FIGURE 3. The color-coded fixture mounts are prepared as transitional abutments for immediate loading. FIGURE 4. Impression posts are attached to the implants.

before preparation for implant placement. A mucoperiosteal flap was elevated in most cases but was kept small to preserve the periosteal vascular supply. In other cases, a flapless, transmucosal surgical approach was utilized to preserve the vascular network, natural soft tissue contours, and esthetics of the case.

In cases with preexisting partial edentulism, the surgical template was used as a guide to drill

a pilot hole into the residual ridge under copious external irrigation. A sterile, surgical try-in pin (PureForm) was inserted into the guide drill hole, and a plastic try-in coping was placed on the pin to evaluate its emergence profile and location of the proposed restoration relative to the adjacent dentition. The try-in components were removed from the patient's mouth. In immediate extraction sites, the surgical template and

natural dimensions of the socket provided appropriate surgical orientation and thus obviated the need for the component try-in.

The implant receptor site was initially prepared in the tooth extraction socket or residual ridge by sequential cutting with a series of internally irrigated straight drills in progressive diameters. A final-step drill was used to prepare the apical end of the definitive osteotomy 0.2 mm smaller

in diameter than the tapered apical end of the implant. This allowed approximately one third of the tapered implant to be placed before its self-tapping apical threads engaged the lateral walls of the receptor site. As the implant was placed, its tapered body progressively condensed the bone from 0.2 mm at the apex to 0.3 mm at the crest of the ridge, which completely eliminated any voids around the cervical end of the implant (Figure 2). The fixture mount was oriented toward the buccal aspect according to the manufacturer's recommendations for abutment positioning.

After the implant was placed, the fixture mount was prepared as a transitional abutment, and a nonoccluding, provisional prosthesis (Figure 3) was immediately delivered in some cases. In other cases, the fixture mount was removed and a surgical cover screw was attached. The soft tissues were reapproximated and sutured around the provisional restoration for 1-stage healing or over the top of the implant for a conventional 2-stage surgical procedure, depending on the case. Sutures were removed after approximately 1 week. Antibiotic prophylaxis (eg, amoxicillin 500 mg) was commenced immediately before surgery and continued for 3 days postoperative.

Healing was approximately 4 months for submerged implants and 2 weeks for immediately provisionalized implants. At the end of this phase, submerged implants were surgically uncovered and evaluated clinically and radiographically for osseointegration. The implants were immediately provisionalized, and the soft tissue was closed around the nonoccluding prosthesis with 3-0 sutures (Vicryl, Ethicon, Somerville, NJ). The sutures were removed approximately 5 days

later, and the soft tissue was allowed to mature for approximately 2 weeks before definitive restorative procedures began.

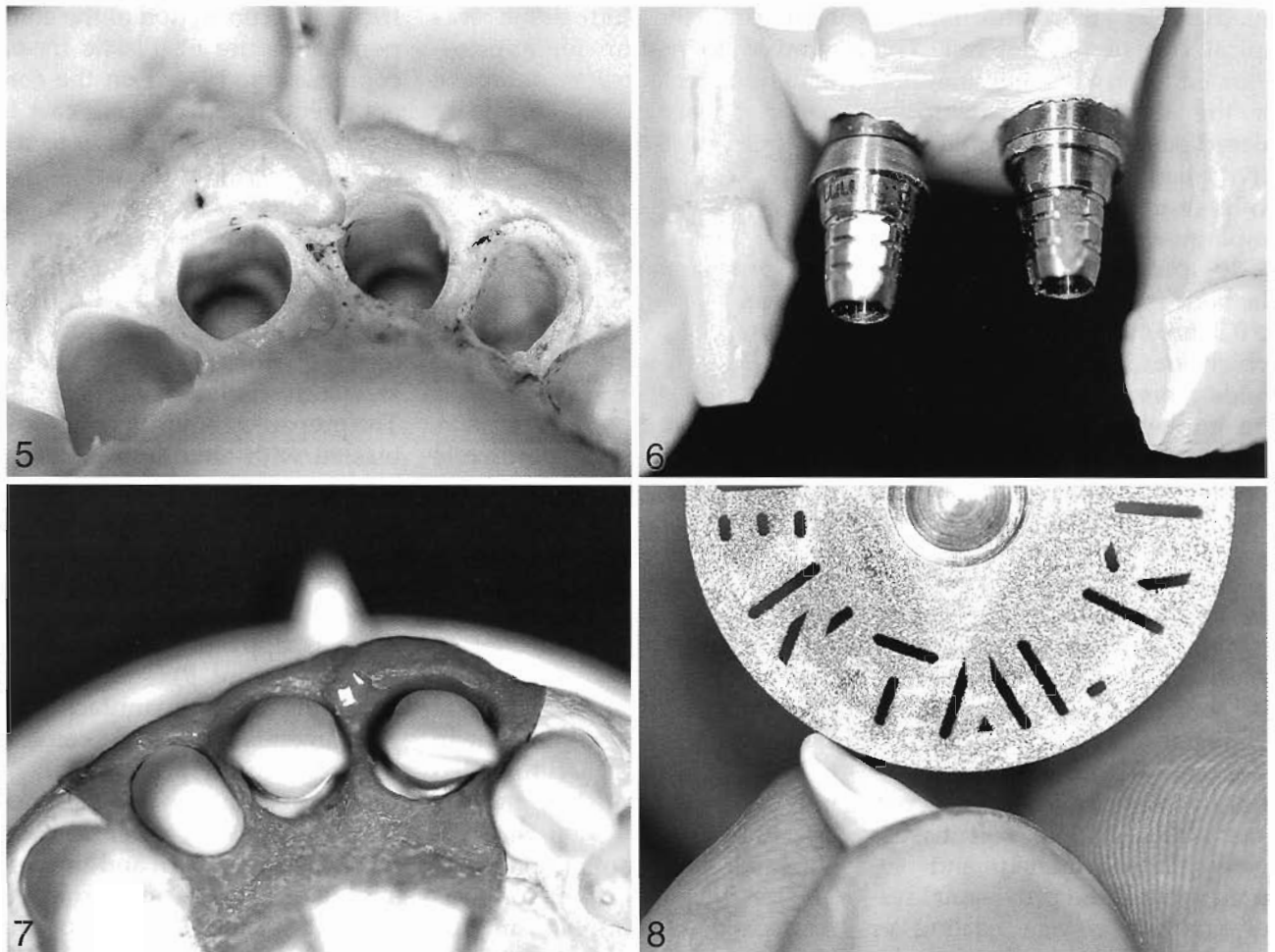
Definitive restoration procedures

The provisional prosthesis was removed, an impression post was attached to the implant (Figure 4), and the screw-access hole in the top of the component was blocked out with utility wax. A full-arch impression was made with an elastomeric material (eg, vinyl polysiloxane) (Figure 5). After setting, the impression was removed from the patient's mouth, and the area surrounding the posthole was lubricated in the impression with petroleum jelly. The impression post was unthreaded from the implant in the patient's mouth and threaded into an implant analog, and the assembly was inserted into the corresponding impression hole. The provisional restoration was reattached to the implant, and the patient was dismissed until delivery of the definitive prosthesis.

In the dental laboratory, soft tissue replication material (eg, IPS Express, Ivoclar Williams, Amherst, NY) was injected around the transfer assembly, the impression was poured in dental stone, and the working cast was separated after setting. The impression post was removed from the implant analog incorporated within the working cast. A core abutment (PureForm) was selected according to its cuff height (0.5 mm or 1.5 mm) based on the depth of the peri-implant sulcus replicated on the working cast. The component was placed on the implant analog in the working cast with its flat side oriented buccally, and was stabilized with a retaining screw tightened to 30 Ncm of torque to fully engage the

friction-fit connection of the component (Figure 6). Plastic try-on copings were placed on the core abutment in the working cast to evaluate its shape relative to the adjacent dentition (Figure 7). After selection of a coping in the optimum dimensions, a corresponding ceramic coping was reduced and contoured with high-speed diamond wheels and external irrigation to prevent excessive heat generation (Figure 8). The prepared ceramic coping was blasted with aluminum oxide at 38 psi and steam cleaned for 45 seconds. Porcelain with a coefficient of thermal expansion that ranged from 8.1 to 8.3×10^{-6} (eg, Vitadur Alpha, Vident, Brea, Calif) was applied to the ceramic coping (Figure 9) and finished according to the manufacturer's recommendations and conventional laboratory procedures.

In preparation for sterilization, the finished ceramic prosthesis was removed, and the core abutment was unseated from the implant analog in the working cast with a removal tool that dislodged the friction-fit interface between the abutment and implant analog. At the delivery appointment, the provisional prosthesis was removed from the implant, and the sterilized core abutment was delivered to the implant with 30 Ncm of applied torque (Figure 10). Full seating of the core abutment was verified radiographically. The screw-access hole in the top of the core abutment was occluded with a cotton pellet and composite material to prevent the ingress of cement and to facilitate its future retrieval. The porcelain single-tooth prosthesis was luted onto the core abutment with glass ionomer (eg, Ketac-Cem, 3M Espe AG, Seefeld, Austria) or resin (eg, Panavia, Kuraray Co Ltd, Osaka, Japan) cement. Excess cement



FIGURES 5-8. FIGURE 5. A full-arch impression is made with hard- and light-body material. FIGURE 6. The working cast is poured, and the titanium core abutments are selected according to optimum collar height. Abutment diameters are selected according to the color-coded implant analogs. FIGURE 7. The ceramic tooth-shaped copings are placed onto the titanium core abutments for evaluation of contours and needed preparations. FIGURE 8. Adjustments to the ceramic coping are made with a rotating disk. Copious external irrigation is recommended to reduce heat generation.

was removed from the margin area, and the occlusion and bite were adjusted with conventional clinical techniques for porcelain restorations (Figures 11 and 12). Patients were provided with detailed oral hygiene instructions and dismissed. Recall appointments were scheduled for 1 month postrestoration and every 3 months thereafter.

Patient satisfaction survey

At the first follow-up appointment, patients were asked to rate their satisfaction with the definitive restoration in 6 different

categories: esthetics of prosthesis, comfort of prosthesis, function of prosthesis, length of treatment time, meets my expectations, and cost of treatment.

RESULTS

Patient and treatment data are presented in Table 2. A total of 18 patients (9 men, 9 women) ranging in age from 18 to 62 years (mean = 42.4, mode = 18) were selected as study participants and treated with 22 implants (MTX surface = 20, HA-coated surface = 2) and single-tooth restorations.

A total of 19 implants were placed into immediate extraction sockets, and 3 implants (case nos. 13, 15, and 18) were placed into preexisting edentulous locations. Whereas 8 implants (case nos. 8, 9, 13, 14, and 16-18) were immediately provisionalized at the time of implant placement, the remaining 14 implants (case nos. 1-7, 10-12, and 15) were provisionally restored after a submerged healing period. There were no surgical complications, and all implants clinically osseointegrated. After clinical loading with the definitive restoration,

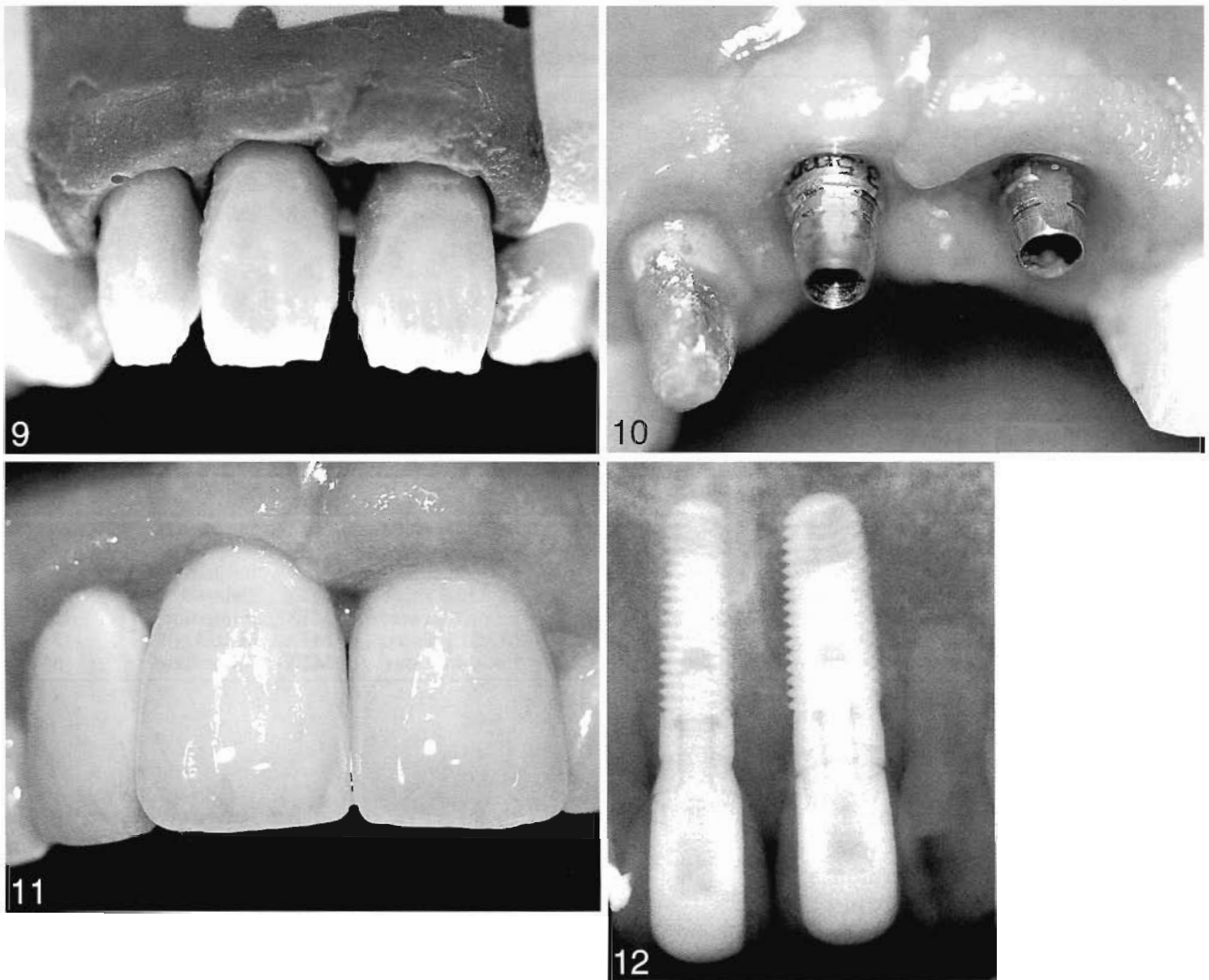


FIGURE 9–12. FIGURE 9. Porcelain is added to the ceramic copings according to conventional laboratory procedures. FIGURE 10. The titanium core abutments are attached to the implants under 30 Ncm of applied torque. FIGURE 11. The all-ceramic crowns are cemented onto the titanium core abutments. FIGURE 12. Radiograph of the finished case.

patients were monitored from 7 to 30 months (mean = 18.1, mode = 18).

Patient health risk factors and adverse events are listed in Table 3. Two patients were habitual smokers. These patients were advised of the higher risk of implant failure and were presented with smoking-cessation options¹⁷ but were included in the study even if they continued smoking. In these 2 patients, smoking did not seem to impair healing, and both restorations continue to function without any adverse clinical manifestations.

One incidence of screw loosening occurred in case no. 3. Examination revealed signs of parafunctional bruxism, which was previously undetected. It was theorized that excessive lateral forces on the implant restoration exceeded the preload value of the abutment screw and caused it to loosen. The definitive prosthesis was removed, and the abutment screw was retightened to 30 Ncm of applied torque. A new ceramic prosthesis was delivered, and a night guard was fabricated for the patient. No further screw loosening occurred.

In case no. 17, the patient presented with a complaint of masticatory discomfort after 13 days of immediate, nonoccluding provisional loading and 1 week after delivery of the definitive prosthesis. Several other teeth were missing, and the patient exhibited signs of malocclusion. The prosthesis was removed and the implant was submerged beneath the soft tissue for 6 months of additional healing. During the submerged healing period, occlusal adjustments were made and additional implants were placed into the remaining edentulous

TABLE 2
Patient treatment and data

Patients			Location		Surgery				Prosthetic Loading Time	Follow-up (mo)
Case No.	Sex	Age	Maxillary Quadrant	Tooth	Surgical Flap	Tooth Removal	Implant Placement	Implant Surface*		
1	F	38	Left anterior	Central incisor	Yes	Yes	Extraction socket	MTX	Delayed	30
2	F	48	Right anterior	Lateral incisor	Yes	Yes	Extraction socket	MTX	Delayed	30
			Right anterior	Central incisor						
			Left anterior	Central incisor						
			Left anterior	Lateral incisor						
3†	M	51	Left anterior	Lateral incisor	Yes	Yes	Extraction socket	MTX	Delayed	24
4	F	18	Left anterior	Central incisor	Yes	Yes	Extraction socket	MTX	Delayed	18
5	M	18	Right anterior	Lateral incisor	Yes	Yes	Extraction socket	MTX	Delayed	24
6	F	49	Left posterior	Second premolar	Yes	Yes	Extraction socket	MTX	Delayed	18
7	F	50	Left posterior	Second premolar	Yes	Yes	Extraction socket	MTX	Delayed	18
8	F	40	Left posterior	Second premolar	No	Yes	Extraction socket	MTX	Immediate	18
9	M	52	Left posterior	Second premolar	No	Yes	Extraction socket	MTX	Immediate	12
10	F	18	Right anterior	Lateral incisor	Yes	Yes	Extraction socket	MTX	Delayed	12
11	M	53	Left anterior	Central incisor	Yes	Yes	Extraction socket	MTX	Delayed	7
12	F	51	Right anterior	Cuspid	Yes	Yes	Extraction socket	MTX	Delayed	7
13	M	32	Right anterior	Central incisor	Yes	No	Residual ridge	MTX	Immediate	25
			Left anterior	Central incisor	No	Yes	Extraction socket	HA		
14	F	47	Left anterior	Central incisor	No	Yes	Extraction socket	HA	Immediate	25
15‡	M	41	Left posterior	First premolar	Yes	No	Residual ridge	MTX	Delayed	25
16	M	49	Right posterior	First premolar	No	Yes	Extraction socket	MTX	Immediate	13
17†	M	62	Right posterior	First premolar	Yes	Yes	Mixed protocol	MTX	Mixed protocol	12
18†	M	46	Left posterior	First premolar	Yes	No	Residual ridge	MTX	Immediate	8

*MTX indicates microtextured; HA, hydroxyapatite.

†Smoker.

‡See Table 3.

areas. All implants subsequently osseointegrated and were successfully restored with the ceramic components used in this study but were not included as part of the study. Correct occlusion was fully restored, and the patient reported no further complications.

Patient response to treatment is presented in Table 4. All patients were very satisfied with the esthetics, comfort, and function of the definitive restoration and with how it met their expectations. One patient (case no. 17) was somewhat satisfied with the length of treatment because of the necessary change in treatment protocol required to address the adverse event. Patients whose implants were immediately loaded (case nos. 8, 9, 13, 14, 16, and 18) were very satisfied with length of treatment, and all other patients indicated that they were satisfied with treatment. All patients were satisfied with the cost of treatment.

DISCUSSION

In the present study, the selected implant featured a 1° taper, which has been reported to offer better primary stability than standard straight screw implants without causing any negative bone tissue reactions related to the tapered screw design.¹⁸ The surgical tech-

nique for low-density bone was designed to compress the bone progressively from 0.2 mm at the apex to 0.3 mm at the crest of the ridge. Research has shown that when a receptor site is prepared a minimum 0.1 mm smaller in diameter than the implant, the force-fitting stresses generated during placement will increase

TABLE 3
Patient health risk factors and adverse events

Case No.	Category	Description	Cause	Treatment
15	Health risk factor	Smoker	Nicotine addiction	Presented with smoking-cessation protocol
18	Health risk factor	Smoker	Nicotine addiction	Presented with smoking-cessation protocol
3	Adverse event	Abutment screw loosened	Parafunctional bruxism	Tightened the abutment screw and fabricated a new prosthesis and night guard
17	Adverse event	Chewing pain	Malocclusion	Submerged the implant for additional healing and balanced the occlusion by placing more implants

TABLE 4
Patient survey results: response to treatment

Clinical Result	Case No. and Patient Assessment of the Clinical Result*																	
	1	2	3	4	5	6	7	8	9	10	11	12	13	14	15	16	17	18
Esthetics of prosthesis	A	A	A	A	A	A	A	A	A	A	A	A	A	A	A	A	A	A
Comfort of prosthesis	A	A	A	A	A	A	A	A	A	A	A	A	A	A	A	A	A	A
Function of prosthesis	A	A	A	A	A	A	A	A	A	A	A	A	A	A	A	A	A	A
Length of treatment time	B	B	B	B	B	B	B	A	A	B	B	B	A	A	A	A	C	A
Meets my expectations	A	A	A	A	A	A	A	A	A	A	A	A	A	A	A	A	A	A
Cost of treatment	B	B	B	B	B	B	B	B	B	B	B	B	B	B	B	B	B	B

*A indicates very satisfied; B, satisfied; C, somewhat satisfied.

insertion torque and implant stability, particularly if the implant has a roughened surface.^{16,19,20} This technique is designed to produce axial and lateral densification of low-density bone and achieve maximum thread engagement along the entire implant body for immediate stability in ridges with adequate width.¹⁶ To avoid tearing the crest of narrow ridges, it may be advisable to first expand the bone with a tapered osteotome before bone densification and lateral deformation by the implant.¹⁶

Immediate placement of the tapered implant design into fresh extraction sockets helped maintain the integrity of the ridge by avoiding classic postextraction resorption patterns. It also limited the degree of required labial inclination for implant placement and enabled use of longer and wider-diameter implants than a straight implant body design would allow. A positive correlation between increasing implant length and greater implant survival has been widely documented in the dental literature.^{21,22} The ability to select implants with the appropriate cervical diameter for the socket enabled the emergence profile of the natural tooth root to be replicated without a residual interfacial void between the implant and socket walls in the crestal region and eliminated the

need to overcontour the prosthesis for esthetics.

The brittleness and inability of ceramic materials to provide the same stress-relieving properties as ductile metals have traditionally restricted their use to the lower stress regions of the anterior jaw.²³⁻²⁵ Today, newer blends of ceramic restorative materials offer a range of flexural strengths and the ability to withstand relatively high compressive forces without cracking or chipping.^{2,6,9-11,15,26} This has expanded the clinical applications of all-ceramic materials to include inlays, onlays, and veneers in addition to short-span fixed partial dentures and single-tooth restorations.^{3,4,16} Numerous studies documenting the strength,²⁷⁻³⁵ attributes, and clinical use³⁶⁻⁴⁸ of ceramic restorative materials on both natural tooth^{27-32,36-43} and implant^{33-35,44-48} abutments have recently proliferated in the dental literature. Although significantly fewer studies⁴⁹⁻⁵⁵ have reported the longitudinal clinical performance of ceramic restorative systems on natural tooth or implant abutments, published clinical evaluations that are available have nonetheless demonstrated excellent esthetics and survival rates comparable with reported results for ceramometal crowns.^{2,56-58}

The ceramic restorative system in this study was easy to use and achieved excellent esthetics.

During assembly, a self-locking taper on the male hexagon of the core abutment created frictional resistance against the internal connection of the implant. When fully assembled under 30 Ncm of applied torque, the mated components created a "virtual cold weld" frictional interface that has been documented to completely eliminate abutment rotational micromovements that have been associated with screw loosening in some implant systems.⁵⁹ To remove the core abutment, a special tool was required to first disengage the tight frictional interface with the implant. The core abutments successfully withstood attachment and removal with the appropriate tools without any evidence of distortion or damage.

As patient demands for improved esthetics continue to expand, clinicians will be challenged to find materials that provide sufficient strength to meet those needs. Previously published research on the present system reported that the strength of all 6 tooth-shaped ceramic copings exceeded the range of maximum bite forces associated with the anterior jaw by 46% (fatigue testing) to 70% (17° compression testing).² In the present study, the ceramic restorative system functioned well for implant restorations in the anterior and premolar regions of the jaw.

CONCLUSION

The ceramic system successfully rehabilitated tooth form, function, and esthetics and remained stable without chipping or cracking up to 30 months of clinical follow-up.

ACKNOWLEDGMENT

The authors thank Michael M. Warner, MA, for assistance.

REFERENCES

- Schirolli G. Immediate tooth extraction, placement of a tapered screw-vent implant, and provisionalization in the esthetic zone: a case report. *Implant Dent.* 2003;12:123-131.
- Castellon P, Potiket N, Soltys JL, Johnson J, Zavala J. All-ceramic restorative system for esthetic implant-supported crowns: in vitro evaluations and clinical case report. *Compend Contin Educ Dent.* 2003;24:673-683.
- Kohal RJ, Klaus G. A zirconia implant-crown system: a case report. *Int J Periodontics Restorative Dent.* 2004;24:147-153.
- Swift EJ Jr. All-ceramic bridges. *J Esthet Restor Dent.* 2003;15:261-262.
- Tan BLB, Dunne JT Jr. An esthetic comparison of a metal ceramic crown and cast metal abutment with an all-ceramic crown and zirconia abutment: a clinical report. *J Prosthet Dent.* 2004;91:215-218.
- Spohr AM, Correr Sobrinho L, Consani S, Coelho Sinhoreti MA, Knowles JC. Influence of surface conditions and silane agent on the bond of resin to IPS Empress-2 ceramic. *Int J Prosthodont.* 2003;16:277-282.
- Schillingburg HT, Hobo S, Lowell DW, Jacobi R, Brackett SE. *Fundamentals of Fixed Prosthodontics.* 3rd ed. Chicago, Ill: Quintessence; 1997:433, 455-483.
- Anil N, Bolay S. Effect of tooth-brushing on the material loss, roughness, and color of intrinsically and extrinsically stained porcelain used in metal-ceramic restorations: an in vitro study. *Int J Prosthodont.* 2002;15:483-487.
- Paul SJ, Pietrobon N. Aesthetic evolution of anterior maxillary crowns: a literature review. *Pract Periodontics Aesthet Dent.* 1998;10:87-94.
- Segal BS. Retrospective assessment of 546 all-ceramic anterior and posterior crowns in a general practice. *J Prosthet Dent.* 2001;85:544-550.
- Cho GC, Donovan TE, Chee WWL. Rational use of contemporary all-ceramic crown systems. *Oral Health.* 1998;88:57-64.
- Hurzeler MB, Quinones CR, Strub JR. Advanced surgical and prosthetic management of anterior single tooth osseointegrated implant: a case presentation. *Pract Periodontics Aesthet Dent.* 1994;6:13-21.
- Lee S. All-ceramic crowns. *Dent Asia.* 2001;2:20-23.
- Chanavaz M. Patient screening and medical evaluation for implant and preprosthetic surgery. *J Oral Implantol.* 1998;24:222-229.
- Sugerman PB, Barber MT. Patient selection for endosseous dental implants: oral and systemic considerations. *Int J Oral Maxillofac Implants.* 2002;17:191-201.
- Le Gall MG. Localized sinus elevation and osteocompression with single-stage tapered dental implants: a technical note. *Int J Oral Maxillofac Implants.* 2004;19:431-437.
- Bain CA. Smoking and implant failure—a smoking cessation protocol. *Int J Oral Maxillofac Implants.* 1996;11:756-759.
- O'Sullivan D, Sennerby L, Meredith N. Influence of implant taper on the primary and secondary stability of osseointegrated implants. *Clin Oral Implants Res.* 2004;15:474-480.
- Skalak R, Zhao Y. Interaction of force-fitting and surface roughness of implants. *Clin Implant Dent Relat Res.* 2000;2:219-234.
- Callan DP, Hahn J, Hebel K, et al. Retrospective multicenter study of an anodized, tapered, diminishing thread implant: success rate at exposure. *Implant Dent.* 2000;9:329-336.
- Orenstein IH, Petrazzuolo V, Morris HF, Ochi S. Variables affecting survival of single-tooth hydroxyapatite-coated implants in anterior maxillae at 3 years. *Ann Periodontol.* 2000;5:68-78.
- Winkler S, Morris HF, Ochi S. Implant survival to 36 months as related to length and diameter. *Ann Periodontol.* 2000;5:22-31.
- McLean JW. The science and art of dental ceramics. *Oper Dent.* 1991;16:149-156.
- Zeng K, Oden A, Rowcliffe D. Flexure tests on dental ceramics. *Int J Prosthodont.* 1996;9:434-439.
- Gemalmaz D, Ergin S. Clinical evaluation of all-ceramic crowns. *J Prosthet Dent.* 2002;87:189-196.
- Van Dijken JW. All-ceramic restorations: classification and clinical evaluations. *Compend Contin Educ Dent.* 1999;20:1115-1136.
- Oblak C, Jevnikar P, Kosmac T, Funduk N, Marion L. Fracture resistance and reliability of new zirconia posts. *J Prosthet Dent.* 2004;91:342-348.
- Azer SS, Drummond JL, Campbell SD, Zaki AEM. Influence of core buildup material on the fatigue strength of an all-ceramic crown. *J Prosthet Dent.* 2001;86:624-631.
- Sobrinho LC, Cattell MF, Glover RH, Knowles JC. Investigation of the dry and wet fatigue properties of three all-ceramic crown systems. *Int J Prosthodont.* 1998;11:255-262.
- Lang LA, Wang R-F, Kang B, White SN. Validation of finite element analysis in dental ceramics research. *J Prosthet Dent.* 2001;86:650-654.
- Strub JR, Beschnidt SM. Fracture strength of 5 different all-ceramic crown systems. *Int J Prosthodont.* 1998;11:602-609.
- Proos KA, Swain MV, Ironside J, Steven GP. Finite element analysis studies of an all-ceramic crown on a first molar. *Int J Prosthodont.* 2002;15:404-412.
- Erneklint C, Ödman P, Örtengren U, Rasmusson L. Tolerance test of five different types of crowns on single-tooth implants. *Int J Prosthodont.* 1998;11:233-239.
- Yildirim M, Fischer H, Marx R, Edelhoff D. In vivo fracture resistance of implant-supported all-ceramic restorations. *J Prosthet Dent.* 2003;90:325-331.
- Papavasiliou G, Tripodakis APD, Kamposiora P, Strub JR, Bayne SC. Finite element analysis of ceramic abutment-restoration combinations for osseointegrated implants. *Int J Prosthodont.* 1996;9:254-260.
- Filho AM, Vieira LCC, Araujo E, Baratieri LN. Ceramic inlays and onlays: clinical procedures for predictable results. *J Esthet Restor Dent.* 2003;15:338-352.
- Mrazek WR. Laboratory procedures for fabrication pressable all-ceramic restorations. *J Dent Technol.* 1997;14:10-16.
- Eaves MY, DeZak HV. Maxillary anterior reconstruction using CAD/CAM-processed zirconium-based restorations. *Contemp Esthet Restor Dent.* 2004;8:22-26.
- Poss S, Milne M. Smile enhancement using all-ceramic materials. *Pract Proced Aesthet Dent.* 2004;16:57-59.
- Bindl A, Mörmann WH. An up to 5-year clinical evaluation of posterior In-

Ceram CAD/CAM core crowns. *Int J Prosthodont.* 2002;15:451-456.

41. Raigrodski AJ, Saltzer AM. Clinical considerations in case selection for all-ceramic fixed partial dentures. *Pract Proced Aesthet Dent.* 2002;14:411-419.

42. Esquivel-Upshaw JF, Chai J, Sansano S, Shonberg D. Resistance to staining, flexural strength, and chemical solubility of porcelains for all-ceramic crowns. *Int J Prosthodont.* 2001;14:284-288.

43. Sevük Ç, Gür H, Akkayan B. Copy-milled all-ceramic restorations: case reports. *Quintessence Int.* 2002;33:353-357.

44. Sadoun M, Perelmuter S. Alumina-zirconia machinable abutments for implant-supported single-tooth anterior crowns. *Pract Periodontics Aesthet Dent.* 1997;9:1047-1053.

45. Morgan VJ. Achieving aesthetics with implant-supported all-ceramic crowns. *Dent Today.* 2001;20:66-67.

46. Fernandes A. Combining the single implant with a CAD/CAM restoration. *Dent Today.* 2001;20:68-73.

47. Heydecke G, Sierraalta M, Razzoog ME. Evolution and use of aluminum

oxide single-tooth implant abutments: a short review and presentation of two cases. *Int J Prosthodont.* 2002;15:488-493.

48. Salinas TJ, Sadan A. Establishing soft tissue integration with natural tooth-shaped abutments. *Pract Periodontics Aesthet Dent.* 1998;10:35-42.

49. Radz GM. An improved pressable all-ceramic system: esthetics, strength and versatility. *Contemp Esthet Restor Dent.* 2001;5:16-25.

50. Monaco C, Ferrari M, Miceli GP, Scotti R. Clinical evaluation of fiber-reinforced composite inlay FPDs. *Int J Prosthodont.* 2003;16:319-325.

51. Schulz P, Johansson A, Arvidson K. A retrospective study of mirage ceramic inlays over up to 9 years. *Int J Prosthodont.* 2003;16:510-514.

52. Lehner C, Studer S, Brodeck U, Schärer P. Short-term results of IPS Empress full-porcelain crowns. *J Prosthodont.* 1997;6:20-30.

53. Kükreker D, Gemalmaz D, Kuybulu EO, Bozkurt FÖ. A prospective clinical study of Ceromer inlays: results up to 53 months. *Int J Prosthodont.* 2004;17:17-23.

54. von Steyern PV, Jönsson O, Nilner K. Five-year evaluation of

posterior all-ceramic three-unit (In-Ceram) FPDs. *Int J Prosthodont.* 2001;14:379-384.

55. Andersson B, Ödman P, Carlsson L, Brånemark P-I. A new Brånemark single tooth abutment: handling and early clinical experiences. *Int J Oral Maxillofac Implants.* 1992;7:105-111.

56. Allen EP, Bayne SC, Brodine AH, et al. Annual review of selected dental literature: report of the Committee on Scientific Investigation of the American Academy of Restorative Dentistry. *J Prosthet Dent.* 2002;88:60-88.

57. Ödman P, Andersson B. Procera Allceram crowns followed for 5 to 10.5 years: a prospective clinical study. *Int J Prosthodont.* 2001;14:504-509.

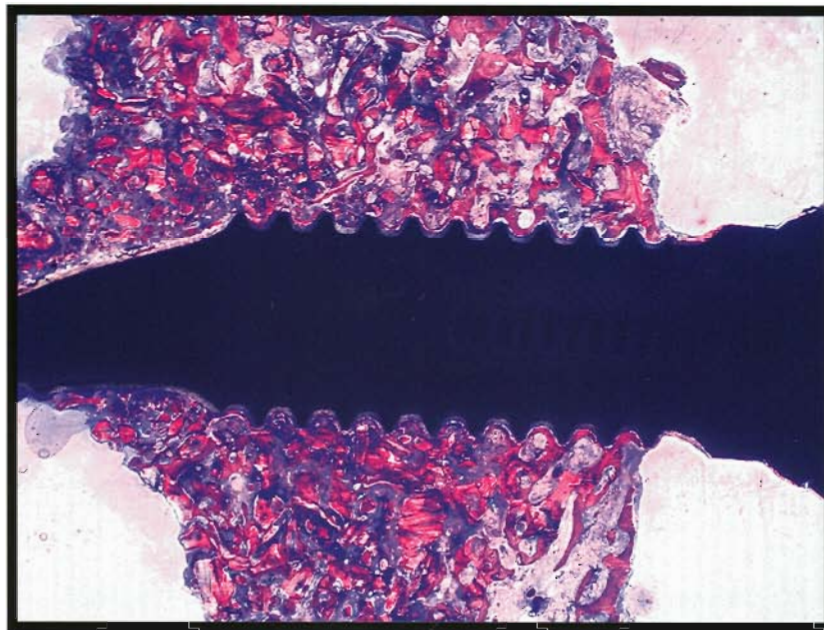
58. Sjögren G, Molin M, van Dijken JWV. A 10-year prospective evaluation of CAD/CAM-manufactured (Cerec) ceramic inlays cemented with a chemically cured or dual-cured resin composite. *Int J Prosthodont.* 2004;17:241-246.

59. Binon PP. The evolution and evaluation of two interference-fit implant interfaces. *Postgrad Dent.* 1996;3:3-13.

JOI

VOLUME 32
NUMBER 4
2006

JOURNAL OF ORAL IMPLANTOLOGY



THE OFFICIAL JOURNAL OF
THE AMERICAN ACADEMY OF IMPLANT DENTISTRY
THE AMERICAN ACADEMY OF IMPLANT PROSTHODONTICS



www.aaid-joi.org