

Strains Recorded in a Combined Tooth-Implant Restoration: An *In Vivo* Study

Zeev Ormianer, DMD,* Tamar Brosh, PhD,† Ben-Zion Laufer, DMD,* and Arie Shifman, DMD†

Implant-supported fixed prostheses are a treatment option to restore missing posterior teeth. Occasionally, it becomes necessary to connect teeth and implants as abutments for these restorations because of anatomical limitations or implant failure to osseointegrate. Whether such restorations can be recommended is a matter of debate. In a 10-year clinical study, no adverse effects were found in combined tooth/implant restorations in the posterior mandible.¹ However, intrusion of the natural teeth is reported as a major clinical complication of such a design, with incidence ranging from 3.4 to 37%.²⁻⁵

Several theories have been proposed to explain this phenomenon, of which the force-distribution theory is the most plausible.⁶⁻⁸ It has been suggested that intrusion could be caused through energy absorption by the implants. Part of this energy is transmitted to the tooth and induces stresses that initiate intrusion because of the differences in mobility between tooth and implant.

The use of nonrigid semiprecision attachments for implant/tooth connection has been suggested to overcome the differences in tooth and implant mobility.⁸ However, a rigid connector may be more suitable for controlling forces transferred from implants to the teeth.⁹⁻¹¹ The purpose of the present study was to compare rigid and nonrigid tooth/implant connections by re-

Implant-supported fixed prosthesis is a treatment option to restore missing teeth. Occasionally, it is necessary to connect teeth and implants as abutments for these restorations. Whether such restorations can be recommended is a matter of debate. This in vivo study measured strains involved in connecting implants to a natural tooth and compared rigid and nonrigid tooth/implant connections. A patient was treated with mandibular unilateral fixed prosthesis supported by two implants and one proximal tooth. Strain gauges were cemented to the experimental framework restoration. Recordings were obtained from the restorations while the patient bit on a wooden stick on the day of placement and after 2 weeks in function, using both rigid and nonrigid attach-

ment connections. A significant difference was found in horizontal deformation of the tooth/crown between day 1 and 2 weeks later. Vertical deformations were smaller than horizontal ones. After applying biting forces, horizontal and vertical deformations were maintained. Strain recorded in a clinical setting revealed mostly horizontal strains generated in a combined tooth/implant device. These strains were maintained after a 2-week recording. Within the limitation of this study, combined tooth/implant restorations could be a potential complication and could cause an intrusion of a natural abutment regardless of the type of connection (rigid or nonrigid). (Implant Dent 2005;14:58-62)

Key Words: tooth-implant combination, strain measurements, intrusion

cording strains generated by occlusal forces.

MATERIALS AND METHODS

Clinical Trial

A 48-year-old male patient received two implants (Omniloc, Calcitek, Carlsbad, CA), each at the mandibular molar area, leaving one tooth space between the proximal implant and the distal premolar tooth. This tooth also needed a full coverage restoration. There were no missing teeth in the maxillary arch. The patient agreed to receive an experimental metal (Argelite 60+, Argon, San Diego, CA) provisional restoration. No signs of temporomandibular disorders or parafunctional habits were evident.

screwed to the implants with a mesial cantilever was connected with a T-block attachment (Combi-Snap, Cendres & M'etaux SA, Biel-Bienne, Switzerland) to a complete-coverage crown section cemented temporarily (TempBond, Kerr Corp., Orange, CA) on the premolar. The matrix of this attachment connection was embedded in the distal aspect of the crown during casting. An occlusal set screw was added to the attachment to optionally convert the design from a nonrigid to a rigid connection (Fig. 1). Housing to accommodate strain gauges and their connectors was prepared in the buccal aspect of the casting of both sections. The provisional restoration was clinically judged to fit passively and used for 2 weeks.

Experimental Restoration

An experimental metal framework (Argelite 60+) consisting of a section

Measuring Device

On the section of the implant close to the attachment, a 45° strain-

*Private practice. Formerly, Department of Prosthodontics, The Maurice and Gabriela Goldschleger School of Dental Medicine, Tel-Aviv University, Tel Aviv, Israel.
†Senior Clinical Lecturer, Department of Prosthodontics, The Maurice and Gabriela Goldschleger School of Dental Medicine, Tel-Aviv University, Tel Aviv, Israel.

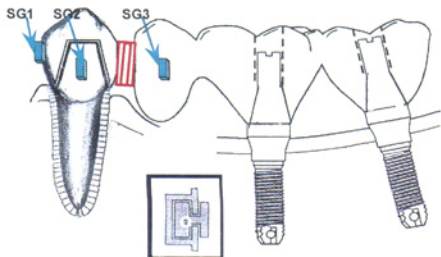


Fig. 1. Schematic representation of restoration framework, optionally combining tooth and implants by rigid and nonrigid attachment. SG1, horizontal strain gauge in crown; SG2, vertical strain gauge in crown; SG3, rosette strain gauge in implant section.

gauge rosette (EA,06031RB-120 Vishay Measurements Group Inc., Raleigh, NC) was cemented (Figs. 2 and 3). Additionally, two linear strain gauges (EA,06030LB-120 Measurements Group, Raleigh, NC) were cemented on the premolar section; one in a vertical position and the other in a horizontal position to measure strains, conforming to buccolingual and occlusogingival tooth movements. Strain gauges were connected to a multichannel strain indicator (2100, Vishay Measurements Group Inc.).

Measuring Procedure

Before measurements, the patient deliberately applied 10 repetitive masticatory forces on the restoration in the intercuspal position and also bit on a wooden stick placed on the implant and premolar sections to attain a baseline recording. The patient was instructed to exert about half of the maximal occlusal force. This procedure was performed alternatively in rigid and nonrigid settings. The measuring procedure was repeated twice: on the day the device was placed and 2 weeks later. Data were recorded using a ViewDec system (Data Acquisition System, Keithley, Asyst, NY).

RESULTS

The horizontal strain measurements of the experimental setting are shown in Figure 4. Deformation in the

experimental setting (Δ L/L) was recorded by strain. At the beginning, horizontal strains were minimal while applying bite forces. There was a difference in horizontal strains of the tooth crown between day 1 and 2 weeks later (Fig. 4). However, no difference between the rigid and nonrigid connection of the segments was evident. The negative direction (*i.e.*, $\Delta -200 \mu$ strain generated in the strain gauge) indicated contraction deformation within the metal framework. After applying biting forces on the wooden stick, smaller vertical strains than the horizontal strains were recorded (Fig. 5). At the initial biting, there was complete recovery of the strains. However, after several biting cycles, there was

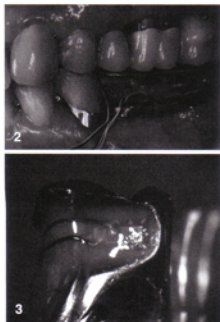


Fig. 2. Measuring device in the mouth.

Fig. 3. Strain gauges cemented to the tooth/crown framework.

no recovery of the horizontal and vertical strains to the baseline (Fig. 5).

DISCUSSION

After several bites, there was no recovery of the horizontal and vertical deformations, although vertical deformations were smaller than the horizontal strains (Fig. 4). Strains accrued after 2 weeks. These results may be attributed to a vertical freedom in the attachment and also to the viscoelastic properties of the periodontal ligament that enable intrusion. It can be taken

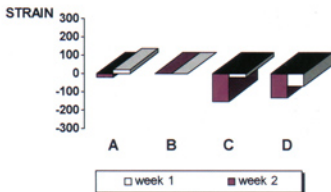


Fig. 4. Horizontal strains measured at 2-week interval. A, implant region, nonrigid attachment; B, implant region, rigid attachment; C, tooth region, nonrigid attachment; D, tooth region, rigid attachment.

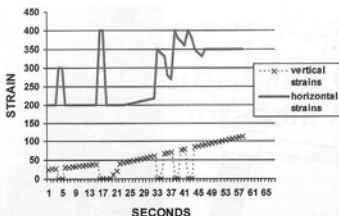


Fig. 5. Horizontal and vertical strains recorded after 2 weeks of using experimental restoration. Note incomplete recovery of strains compared with baseline.

into account that framework construction deformation caused by increased horizontal strains, concomitant with vertical strains, induced locking after 2 weeks in function.

A reversal of tooth intrusion after disconnection of rigid tooth/implant attachment has also been reported clinically.¹² Only a few studies can be found that examine transmission and recording of forces on tooth/implant restoration. Gunne *et al*¹³ measured bending moments when axial load was applied on tooth/implant posterior restorations. Loads were shared between the abutment tooth and the implant, probably caused by the inherent binding flexibility of the implant screw joint. In the present study, a difference in horizontal deformation on the tooth/crown at a 2-week interval was shown (Fig. 4). However, in Gunne *et al*,¹³ the design was different; only vertical recordings, with no time interval, were carried out. In the present study, the duration of measurements did not extend beyond 2 weeks, as deformations were recorded within this time period.

Loading on osseointegrated dental implants is measured preferably *in vivo* using strain gauge methods,¹⁴ as in the present study. Despite the technical difficulties in connecting the strain gauges to the strain indicator because of the watery conditions in the

mouth inherent in the study, additional patients will be used in a future study.

CONCLUSION

Vertical and horizontal strains were generated in a combined tooth/implant prosthetic device. As there was no recovery of the strains generated in the restoration during function, continuous loading may result in vertical strains, causing intrusion of the natural tooth and horizontal strains "locking" this tooth, regardless of the type of connection (rigid or nonrigid).

DISCLOSURE

The authors claim to have no financial interest in any company or any of the products mentioned in this article.

REFERENCES

1. Gunne J, Astrand P, Lindh T, *et al*. Tooth-implant and implant supported fixed partial dentures: a 10 year report. *Int J Prosthodont*. 1999;12:216-221.
2. Garcia LT, Oesterle LJ. Natural tooth intrusion phenomenon with implants. A survey. *Int J Oral Maxillofac Implants*. 1998;13:227-231.
3. Rieder CE, Parel SM. A survey of natural tooth abutment intrusion with implant-connected fixed partial dentures. *Int J Periodontics Restorative Dent*. 1993;13:335-347.

4. Naert IE, Duyck JAJ, Hosny MMF, *et al*. Freestanding and tooth-implant connected prostheses in the treatment of partially edentulous patients. Part I: an up to 15-years clinical evaluation. *Clin Oral Implants Res*. 2001;12:237-244.

5. Naert IE, Duyck JAJ, Hosny MMF, *et al*. Freestanding and tooth-implant connected prostheses in the treatment of partially edentulous patients. Part II: an up to 15-years radiographic evaluation. *Clin Oral Implants Res*. 2001;12:245-251.

6. Sheets CG, Earthmann JC. Natural tooth intrusion and reversal in implant-assisted prostheses: evidence of and a hypothesis for the occurrence. *J Prosthet Dent*. 1993;70:513-520.

7. Sheets CG, Earthmann JC. Tooth intrusion in implant-assisted prostheses. *J Prosthet Dent*. 1997;77:39-45.

8. Pesun IJ. Intrusion of teeth in the combination implant-to-natural-tooth fixed partial denture: a review of the theories. *J Prosthodont*. 1997;6:268-277.

9. English CE. Root intrusion in tooth implant combination case. *Implant Dent*. 1993;2:79-85.

10. Gross M, Laufer BZ. Splinting osseointegrated implants and natural teeth in rehabilitation of partially edentulous patient. Part I: laboratory and clinical studies. *J Oral Rehabil*. 1997;6:83-87.

11. Schlumberger TL, Bowley JF, Maze GI. Intrusion phenomenon in combination tooth-implant restoration: a review of the literature. *J Prosthet Dent*. 1998;80:199-203.

12. Chee WW, Cho G. A rationale for not connecting implants to natural teeth. *J Prosthodont*. 1997;6:7-10.

13. Gunne J, Astrand P, Ahlen K, *et al*. Implants in partially edentulous patients: a longitudinal study of bridges supported by both implants and natural tooth. *Clin Oral Implants Res*. 1992;3:49-56.

14. Glantz P-O, Rangert B, Svensson A, *et al*. On clinical loading of osseointegrated implants. A methodological and clinical study. *Clin Oral Implants Res*. 1993;4:99-105.

Reprint requests and correspondence to:
Zeev Ormianer, DMD
143 Bialik Street
Ramat-Gan, Israel 52523
Phone: +972 3 6124224
Fax: +972 3 6124226
E-mail: ormianer@zahav.net.il